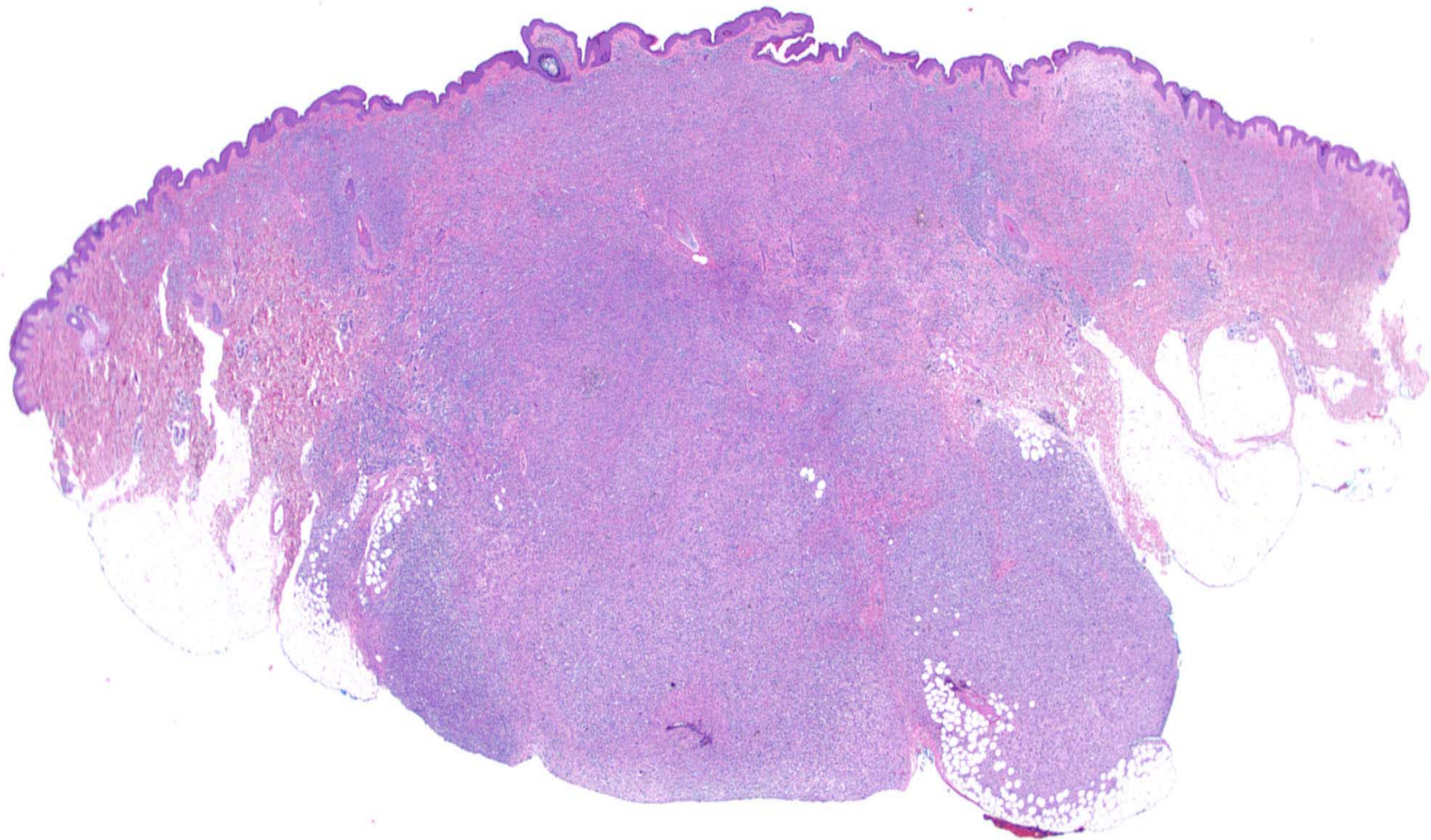
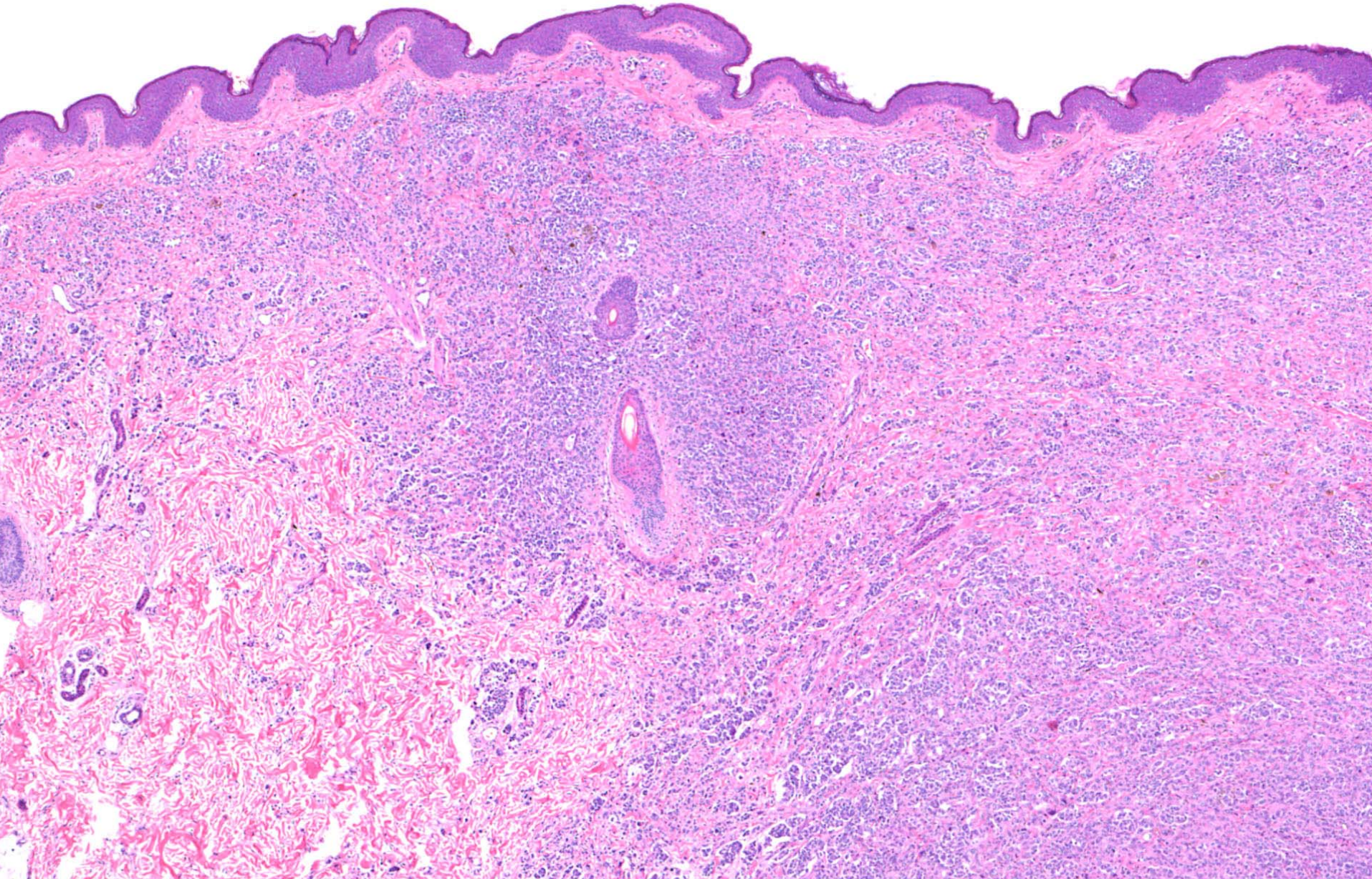
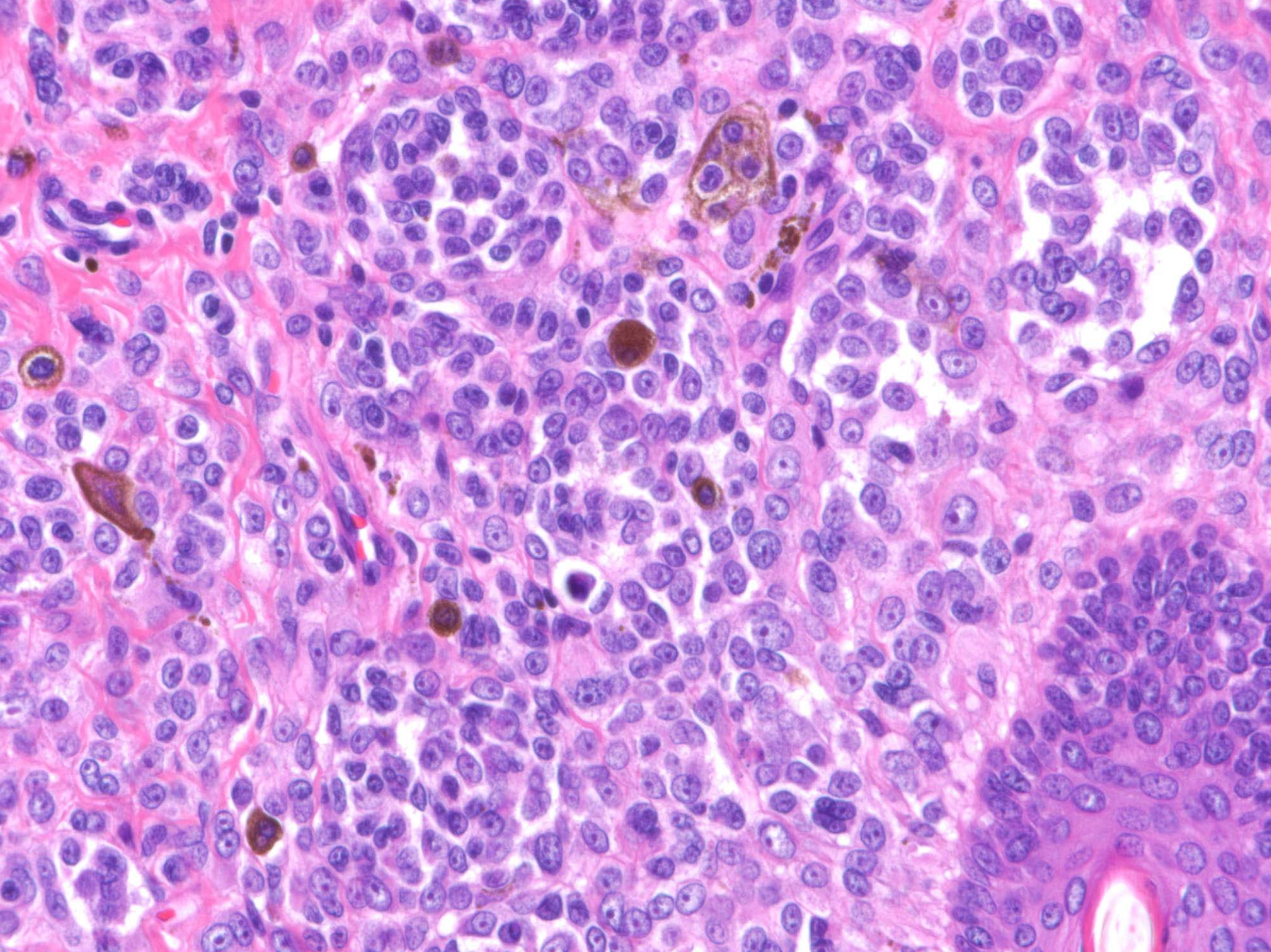


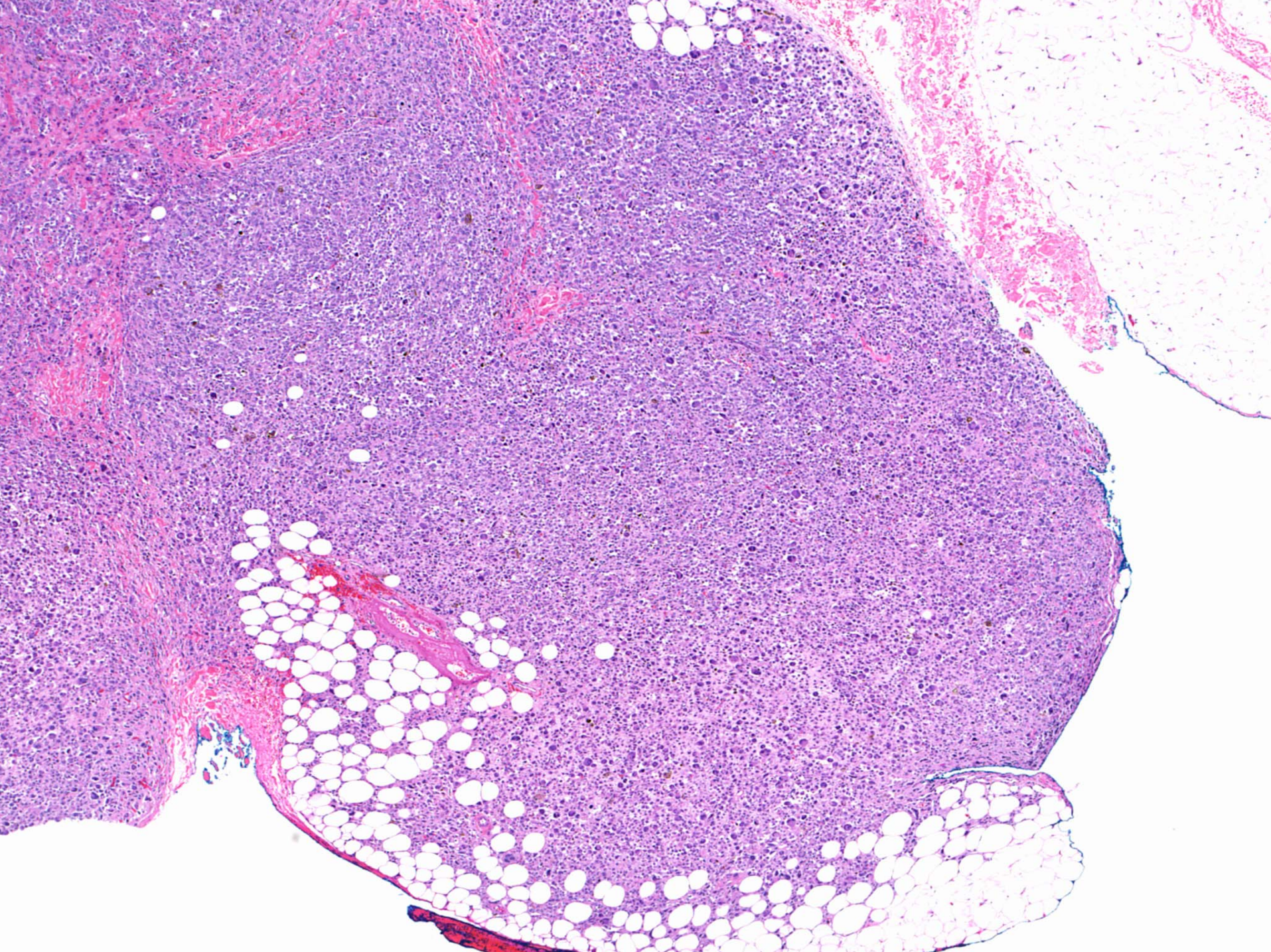
# History

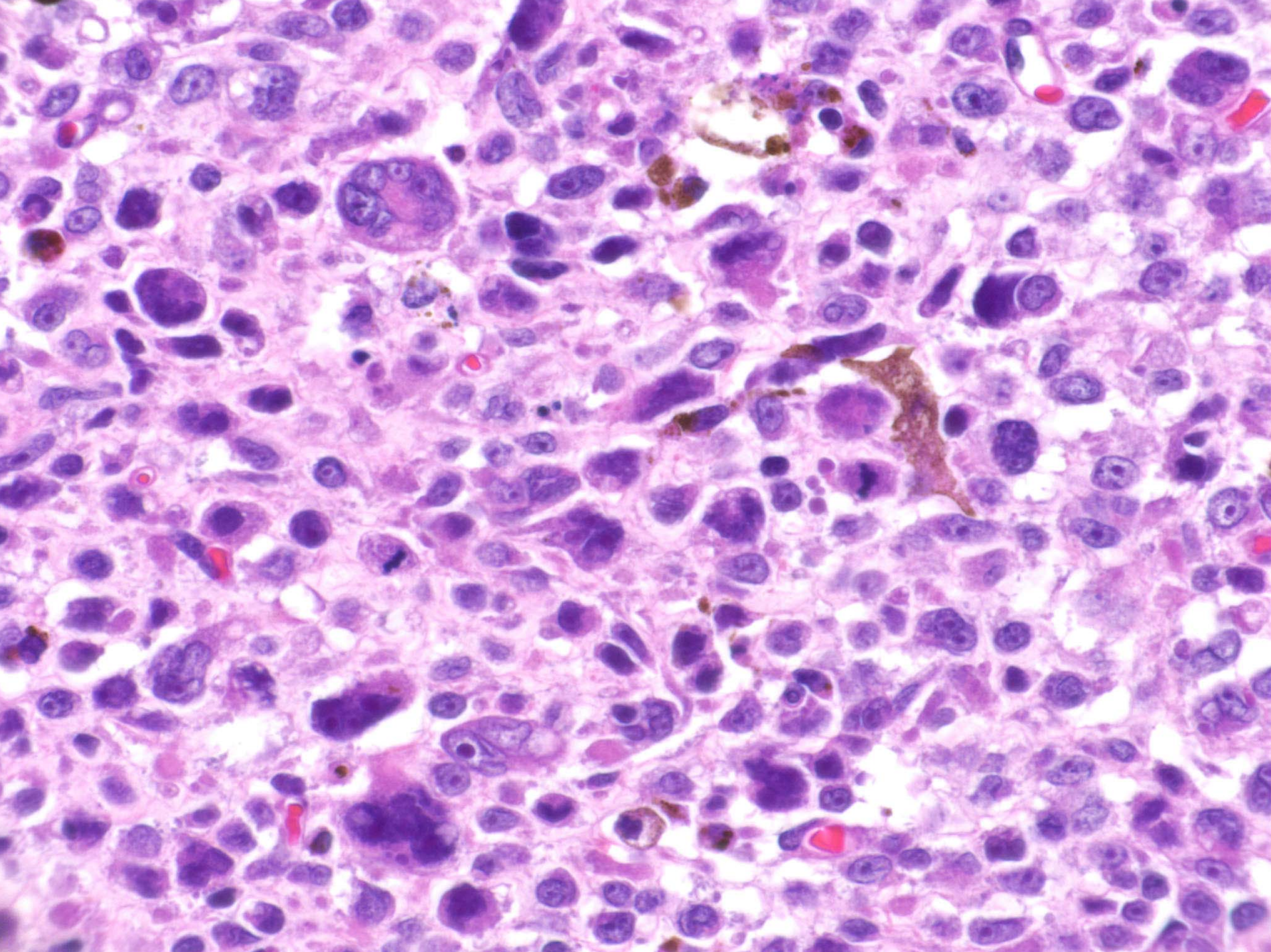
- A three month old male presented with a groin nodule since birth.
- Additional medical history is significant for a large congenital nevus of the scalp; infant is otherwise healthy.
- Representative sections of the groin nodule are provided for review.











What is your diagnosis?