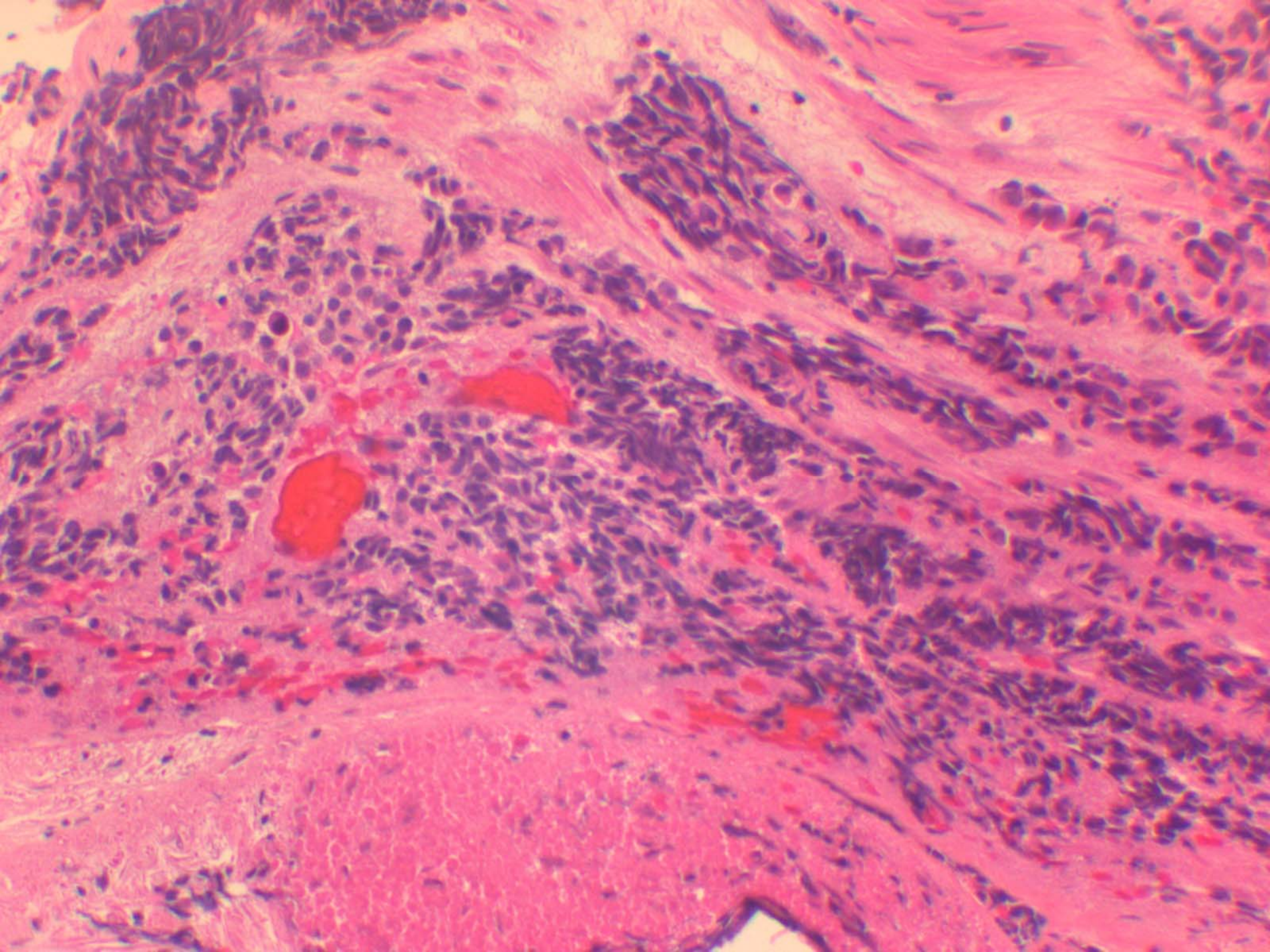
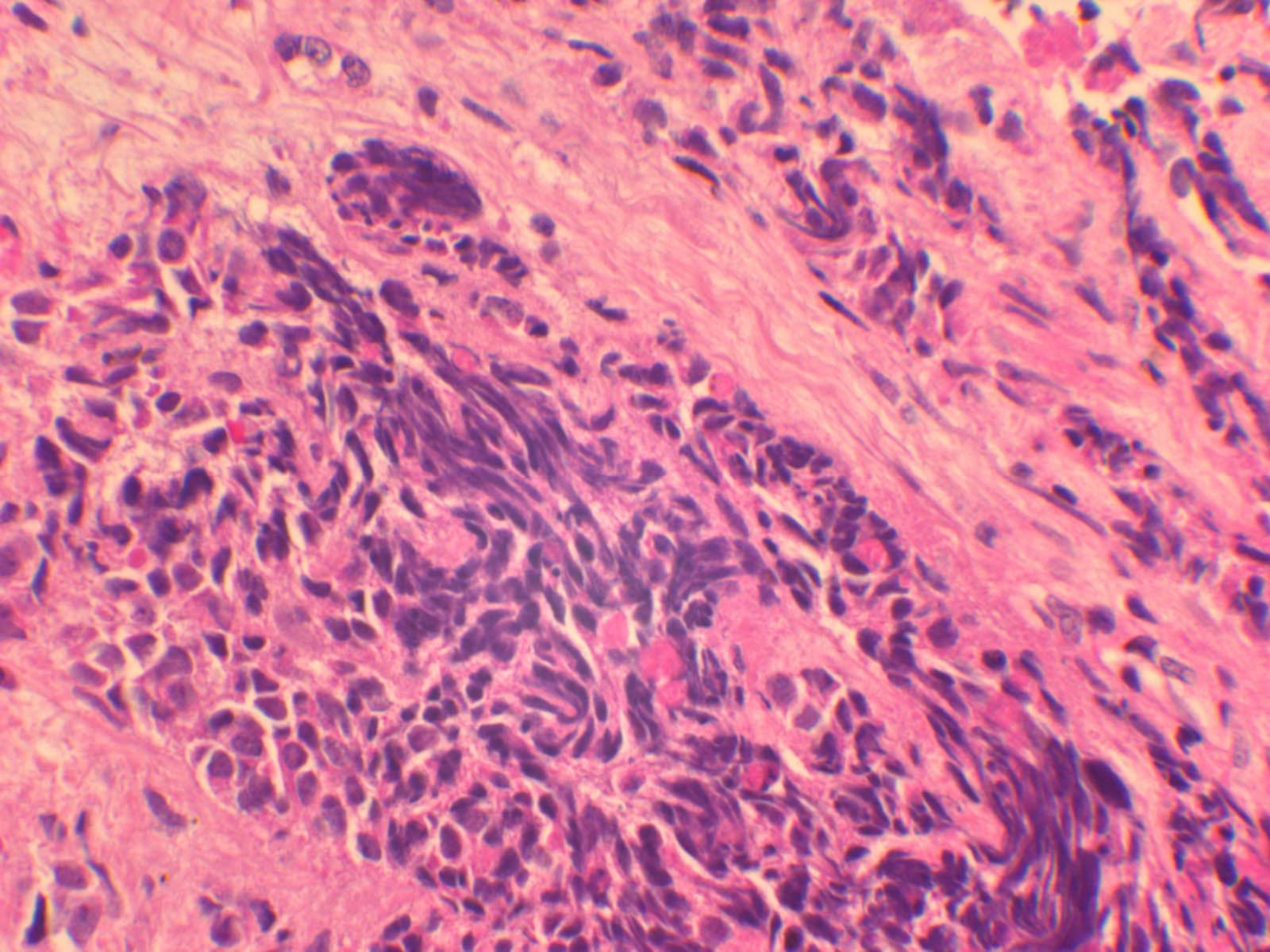


- **72-year old woman with Right Lower Lobe lung mass and probably enlarged mediastinal lymph nodes**
- **Photomicrographs are from her bronchial biopsy**





**What is your diagnosis?**