

Interesting Case

Los Angeles Society of Pathologists

June 9, 2009

Miriam Peckham, PSF

Loma Linda University Pathology Department



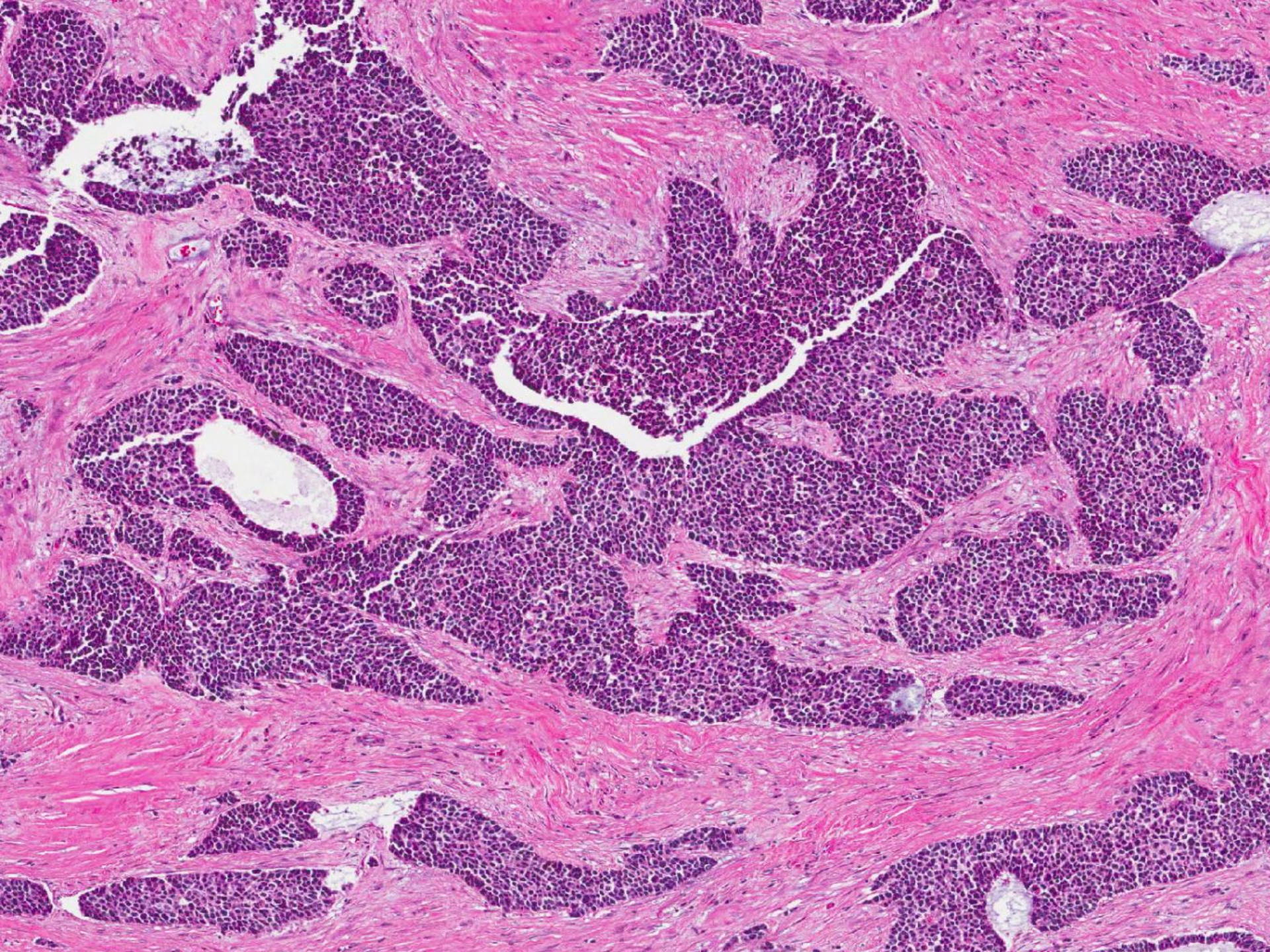
Clinical Presentation

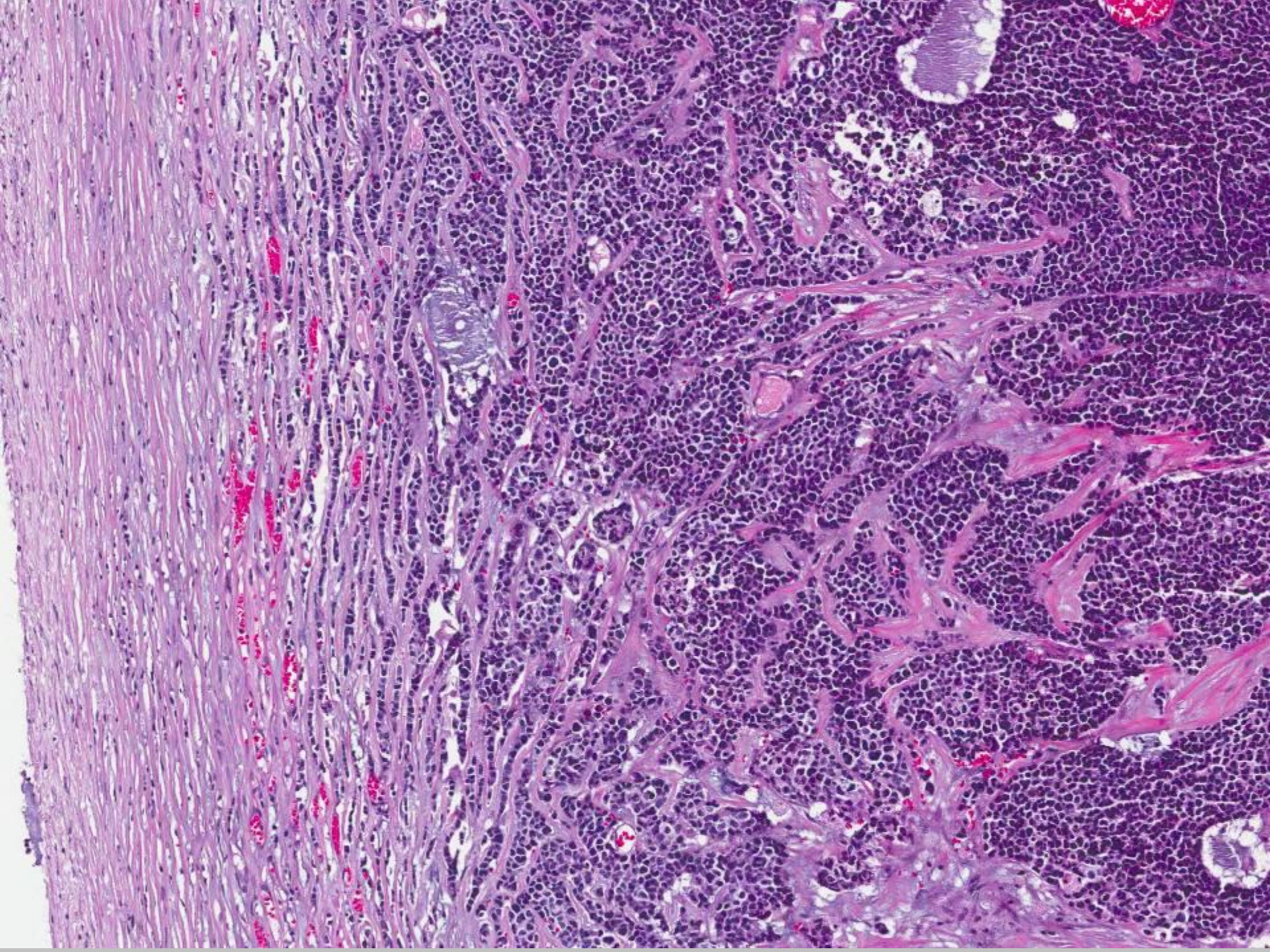
- 28-year-old male
- Left epigastric pain

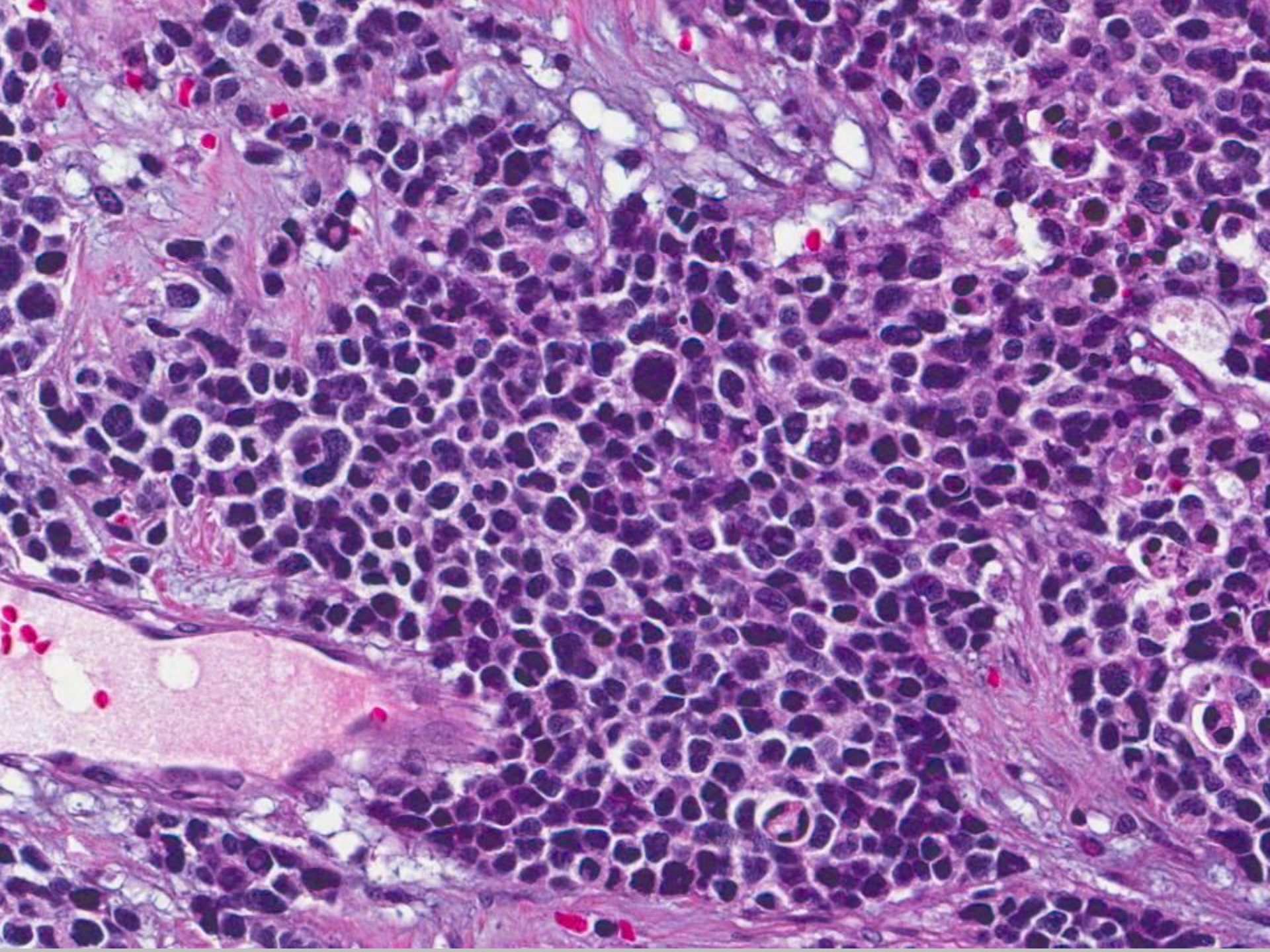


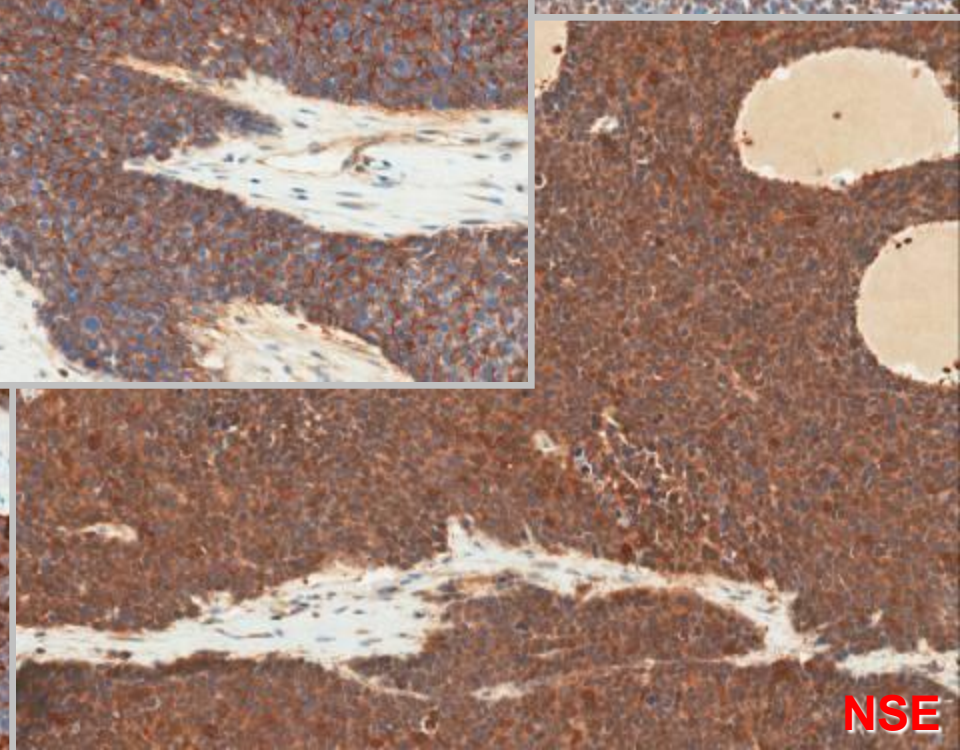
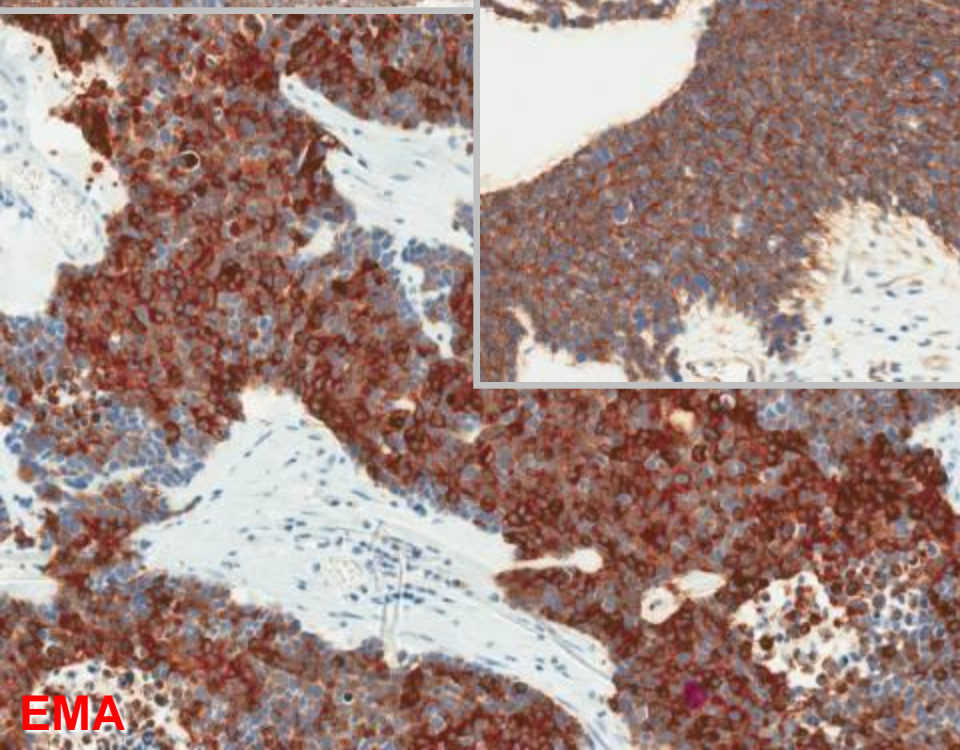
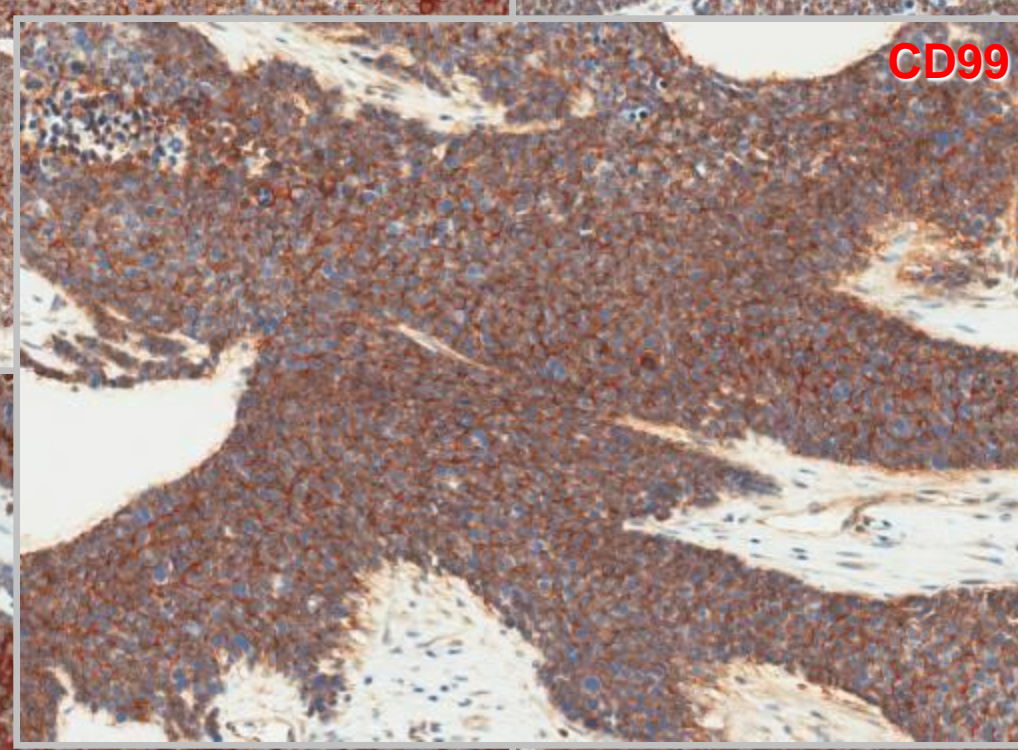
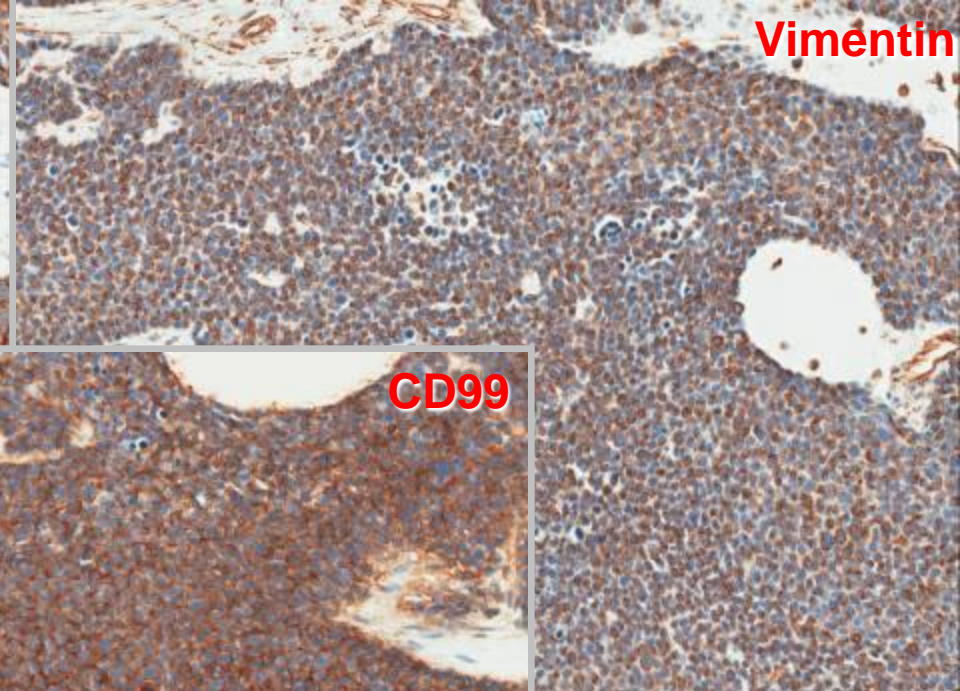
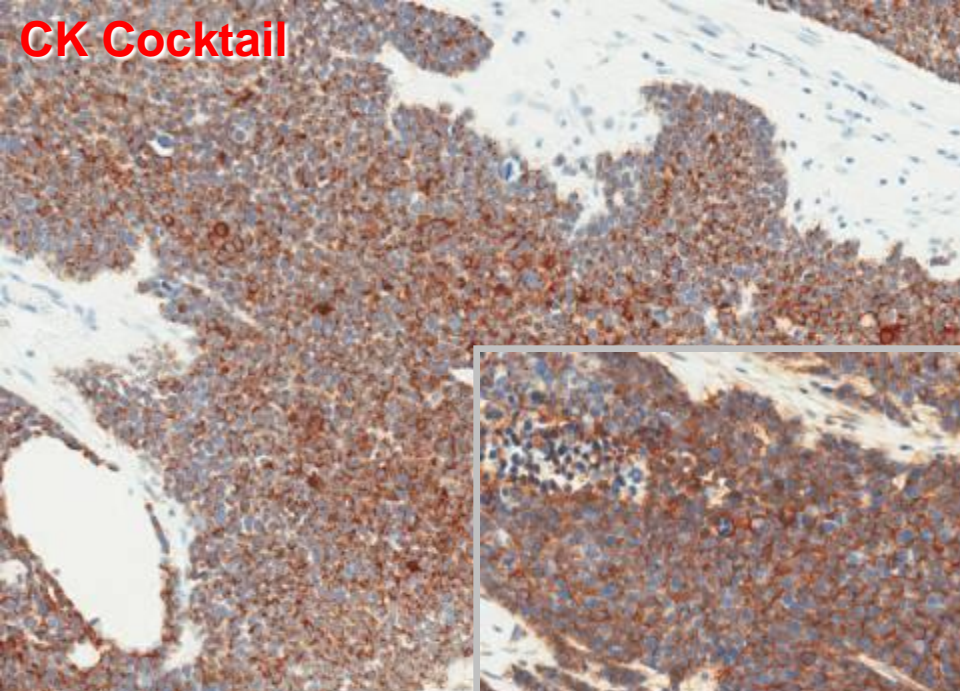
Gross Examination

- 15 cm mass in greater omentum
- Firm, gray-tan heterogenous surface











Immunohistochemistry Profile

Positive for:

- Cytokeratin Cocktail
- Vimentin
- EMA
- NSE
- CD99

Negative for:

- Chromogranin
- GFAP
- S-100
- Desmin

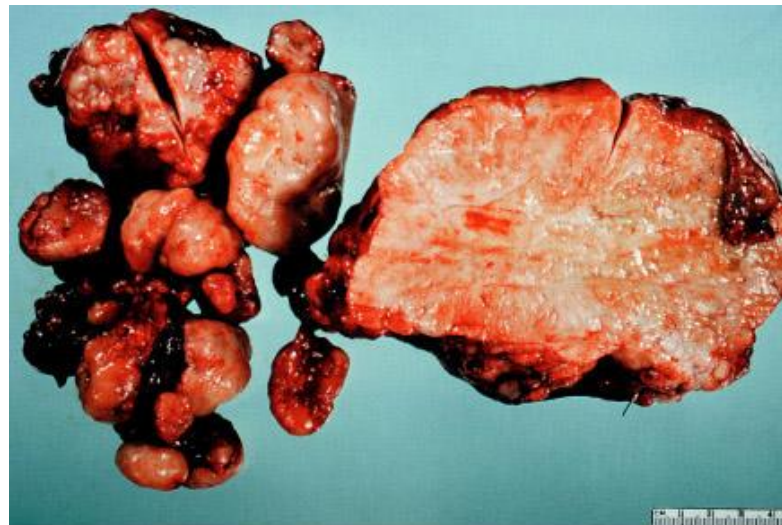A vertical decorative bar on the left side of the slide, featuring a blue gradient with a subtle, ethereal pattern of light and dark blue tones.

Diagnosis

Desmoplastic Small Round Cell Tumor
(DSRCT)

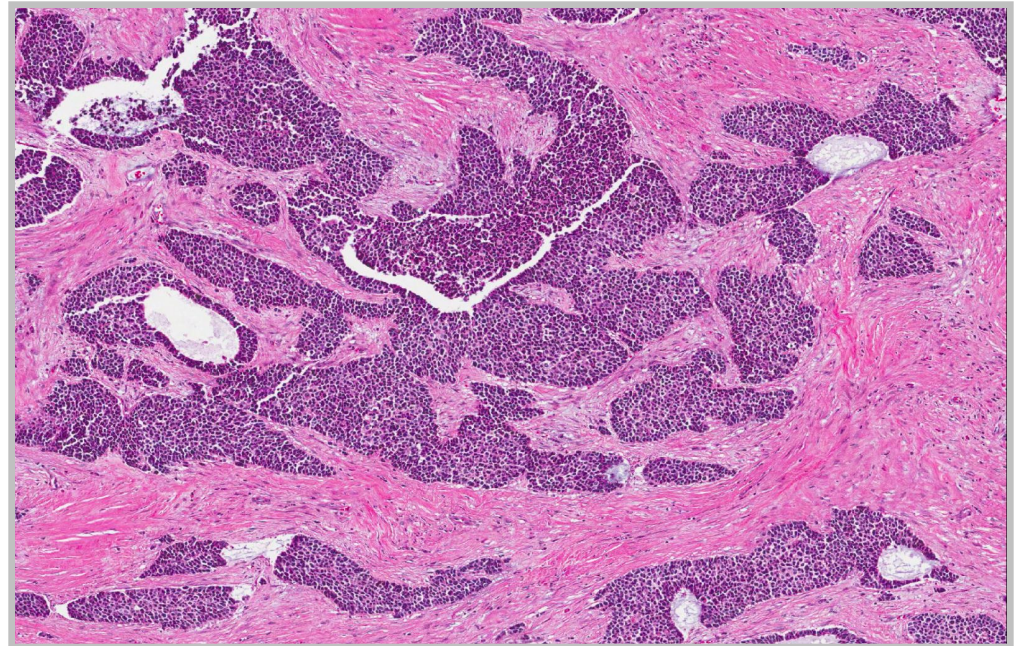
DSRCT

- First described 20 years ago
- Rare
- Young males (15-35)
- Peritoneal based
 - abdomen and pelvis
 - often multicentric or multinodular



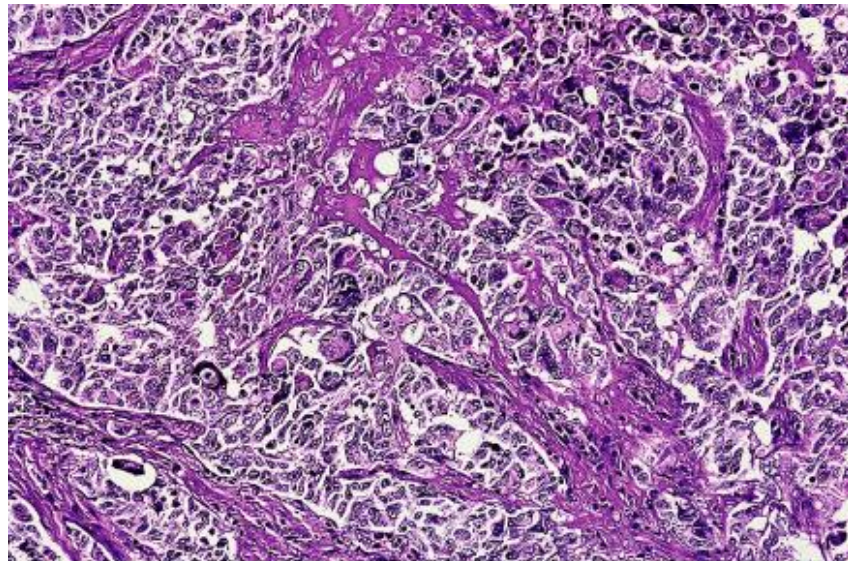
DSRCT

- Lacks definite visceral origin
 - Mesothelial cells?
- Small, round, nested blue cells within a desmoplastic stroma



“Your results may vary”

- Occasionally spindled, rhabdoid, signet-ring or pleomorphic cells



Polyphenotypic

- Shows neural, mesenchymal, and epithelial markers

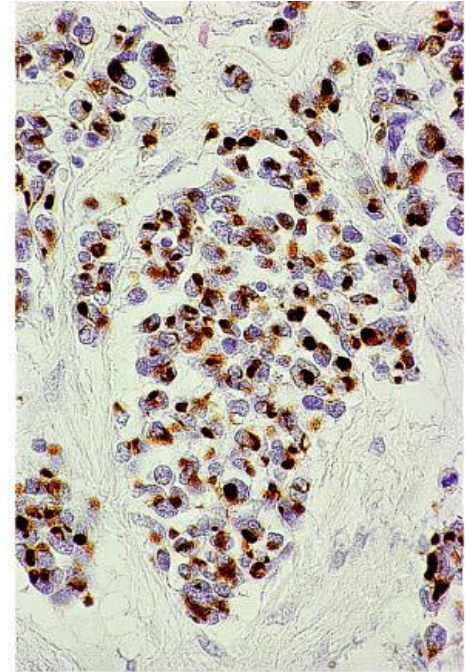
- Majority:

- EMA and cytokeratins
- Vimentin and desmin
- Neuron-specific enolase

- Uncommon:

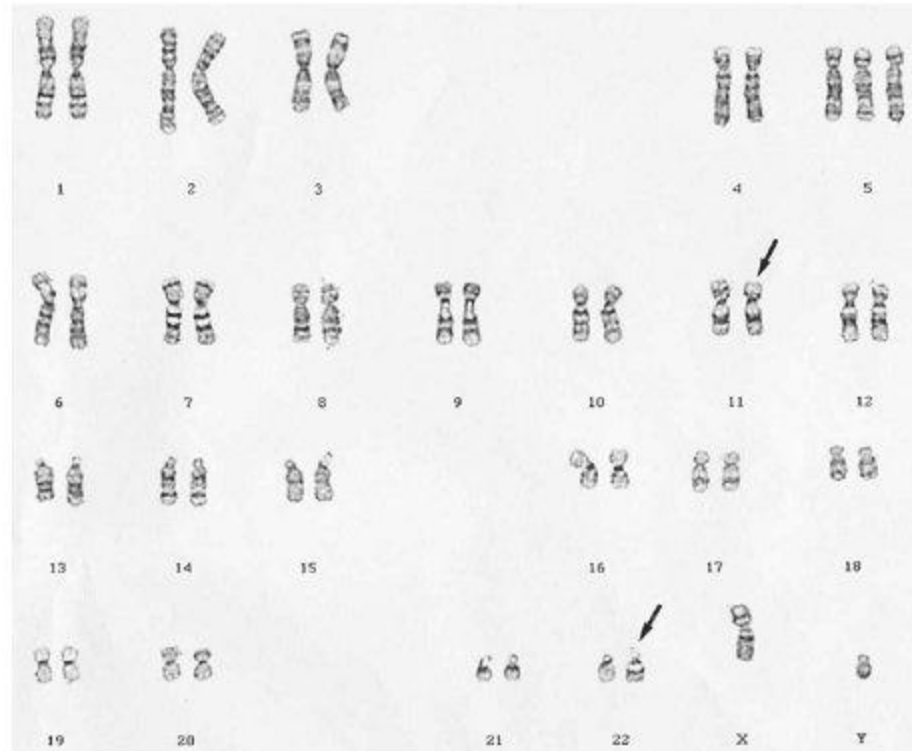- Chromogranin and synaptophysin

- Expresses WT1 - Wilms Tumor Gene



© Elsevier Inc 2004 Rosai and Ackerman's Surgical Pathology

Genetic Characteristics



<http://www.medwave.cl/.../nayo/CursoOnco/MorongFig5.jpg>

Reciprocal translocation of chromosomes 11 and 22

$t(11;22)(p13;q12)$

t(11;22) Translocation

- Fusion of WT1 gene (chromosome 11) and EWS gene (chromosome 22)
- Different fusion product than *t(11;22)* of Ewing's sarcoma

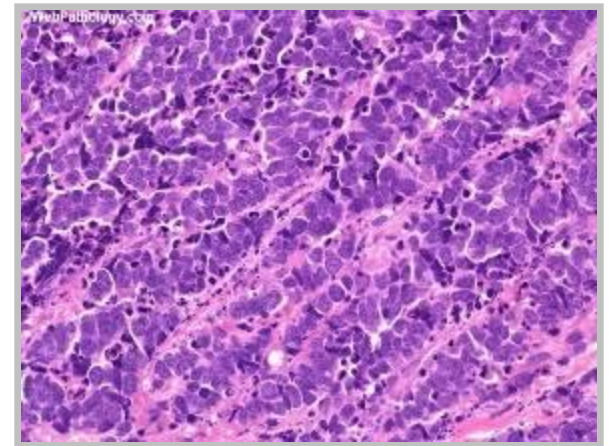
WT1

- EWS-WT1 activates IGF-1
 - Promotes cellular proliferation
- Overexpression
 - Dual expression of mesenchymal and epithelial markers

Differential Diagnoses

- Important to differentiate from other small blue cell tumors

- Small cell carcinoma
- Merkel cell carcinoma
- Poorly-differentiated carcinoma
- Malignant mesothelioma
- Lymphoma
- Rhabdomyosarcoma
- Ewing's sarcoma/PNET
- Wilms tumor
- Neuroblastoma



Differential Diagnoses

- Diagnostic consideration based upon:
 - Age group - Pediatric to young adult?
 - Location - Intra or extra-abdominal?
 - Staining patterns - Polyphenotypic?
- Definitive diagnosis:
 - Presence of *t(11;22)(p13;q12)*



Behavior and Prognosis

- Very aggressive (<2 year survival)
- Often multifocal at presentation

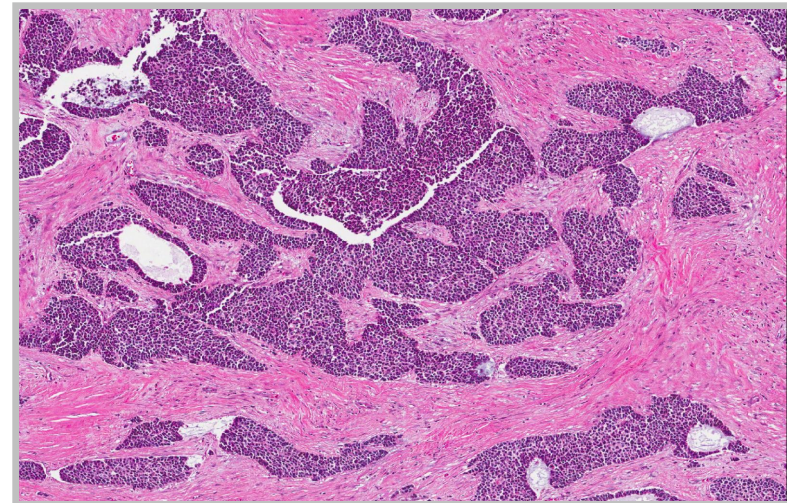


Treatment

- Surgical excision
- Adjuvant chemo and radiotherapy
 - Lal & Sue, et al, showed 55%, 3-year survival with combination therapy

DSRCT—Summary

- Intra-abdominal small round cell tumor of childhood, often multicentric
- Polyphenotypic marker profile
 - Desmin, cytokeratin, NSE
- Characteristic 11;22 translocation
- Aggressive tumor, high mortality



References

1. Weiss SW, Goldblum JR. Soft Tissue Tumors. Mosby Inc. through Elsevier Inc. Philadelphia. 2008.
2. Nader L, Scheithauer BW, Turel KE, Arnesen MA, Ketterling RP, Jin L, Moynihan TJ, Giannini C, Meyer FB. Desmoplastic small round cell tumor of the central nervous system: report of two cases and review of the literature. *Virchows Arch*. 454:431-39, 2009.
3. Hiralal, Gamanagatti S, Thulkar S, Rao SK. Desmoplastic round cell tumour of the abdomen. *Singapore Med J*. 48(1): e19, 2007.
4. Lee Y, Hsiao C. Desmoplastic small round cell tumor: A clinicopathologic, immunohistochemical and molecular study of four patients. *J Formos Med Assoc*. 106(10):854-60, 2007.
5. Murphy AJ, Bishop K, et al. A new molecular variant of desmoplastic small round cell tumor: Significance of WT1 immunostaining in this entity. *Hum Pathol*. 39:1763-70, 2008.
6. Rosai J. Proceedings of the 107th California Tumor Tissue Registry semi-annual seminar, syllabus pages 32-33, December 5, 1999.
7. Lal DR, Su WT, Wolden SL, et al. Results of the multimodal treatment for desmoplastic small round cell tumors. *J Pediatr Surg*. 40:251-5, 2005.

Acknowledgments

- Dr. Don Chase
- Dr. Craig Zuppan
- Dr. Jun Wang
- Dr. Katie Wilkinson
- Pedro Chase

Accepted for publication by the California Tumor Tissue Registry
online journal, July, 2010.

<http://www.cttr.org>